

## **Liver Harvest during Multi Organ Retrieval**

### **INTRODUCTION**

The whole liver can be harvested from two sources.

1. Brainstem dead, heart beating donors/donation after brain death (DBD)
2. Non-heart beating donors/donation after cardiac death (DCD) (at present the Transplantation of Human Organs Act does not permit this kind of donation).

Organ retrieval is generally done at a hospital recognized and accredited with the relevant government authority. It is common practice for the collecting hospital to have first choice of use in single organs and one of the paired organs being retrieved. If the harvesting hospital is not the transplant centre then the organs need to be transported accordingly.

### **DONOR LIVER HARVEST**

Procurement of the donor liver is most often done in conjunction with removal of other organs. Therefore, multiple surgical donor teams must coordinate their efforts to remove organs from the deceased donor as quickly and as effectively as possible. The goals of liver procurement are to: (i) determine if the liver is unacceptable for transplantation, (ii) perform a technically perfect donor hepatectomy, (iii) avoid warm ischaemia of the organs, and (iv) minimize the cold ischaemic time of the donor organs.

Suitability of the donor liver cannot be determined until the liver is visually inspected in the donor's abdomen by an experienced liver transplant surgeon. Even then, the final graft size of the potential recipient with the donor is an important consideration in liver transplantation. Though criteria vary, in general, the donor weight should be within a 25 kg range of the recipient's ideal body weight, or the variance in weights between recipient and donor should not exceed 20%.

The dilemma of the fatty liver during retrieval is based on the centre expertise in handling such grafts and varies with experience. Most centres would reject a liver with >15% fat ascertained after a liver biopsy which can be done even before the retrieval process if a doubt exists or during the retrieval. Liver steatosis is strongly associated, after transplantation, with poor graft function.

Mild to moderate steatosis does not reduce the success rate of liver transplantation and is similar to those achieved with normal function. Livers with more than 40-50% macrosteatosis should not be used. Macrovesicular steatosis is often the result of acute injury and could be reversible, but more than 15% results in impaired post-transplant function. Consequent to such findings, liver biopsy should be performed, but in small hospitals, a pathologist is frequently not available during the night. The best option is to communicate with the recipient centre where, in most of the cases, a pathologist is available during the night.

### ***Duties of personnel during organ retrieval***

1. The transplant coordinator is responsible for ensuring that all donors are tested for:
  - a. HIV I and II Ab
  - b. HbsAg
  - c. HBc-Ab
  - d. Anti HCV-Ab
  - e. CMV-Ab
  - f. Toxoplasma-Ab
  - g. VDRL
2. The lead surgeon of the retrieval team and the coordinator are responsible for performing a risk assessment of the donor to determine any factors that might contribute to an increased risk of transfer of infection or malignancy to the recipient.
3. Before starting the retrieval, the team leader must check the following.
  - a. Brain death criteria are satisfied and recorded correctly
  - b. Cause of death
  - c. Consent for organ donation signed by the next of kin and coroner/police consent.
  - d. Relevant past history and medications
    - i. Jaundice, malignancy, diabetes
    - ii. Hypertension: Check for retinopathy
    - iii. Risk factors for transmission of malignancy
    - iv. Risk factors for transmission of viral and other infections
    - v. Episode of cardio-respiratory arrest or instability
    - vi. Sepsis, hypoxia, hypotension, inotrope support
    - vii. Urine output (last hour and past 24 hours)
    - viii. Blood group virology, liver and renal function tests

### ***Retrieval team***

1. Lead surgeon: Liver team
2. Assistant surgeon: Renal team
3. Additional cardiac team: Two surgeons and Operating Room Technician
4. Anaethetist
5. Scrub nurse
6. Perfusionist
7. Coordinator

The *lead surgeon* is responsible for all aspects of directing the donation, has to discuss aspects of the operation with the anaethetist regarding antibiotic, heparinization and bleed out, write the operation notes and inform the recipient teams of the status of the organ and any problems as well as expected time lines. The *assistant surgeon* assists the lead surgeon and helps in retrieval as directed by the lead surgeon. The *anaethetist* is responsible for donor maintenance during the surgical procedure, administering antibiotics, heparinixation and stopping ventilation and cutting the tape holding the endotracheal tube to prevent marks on the face.

The *scrub nurse* ensures that all special equipment, catheters and fluids are packed and available for moving at a short notice. The other responsibilities include laying out the trolley and assisting during surgery, ensuring two suction lines are available, assist back table perfusion along with the perfusionist, help pack the organs and ensure that the swab and instrument count is correct. The special equipment required for organ retrieval includes:

- a. Large Finochietto retractor
- b. Very large self-retaining abdominal retractor
- c. 30" long Roberts forceps
- d. Laparotomy set
- e. Cannulae for aortic and portal vein perfusion
- f. Cannulae for bench perfusion
- g. Satinsky and bulldog clamps
- h. Gigli/Sternal Saw
- i. 4 plastic bowls and sets of plastic bags with strings
- j. Ice box

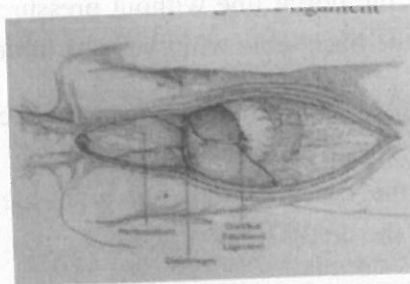
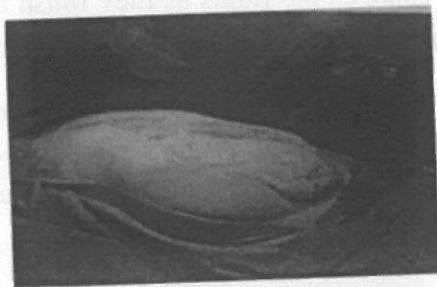
The *perfusionist* ensures that perfusion and other fluids are kept chilled in an ice box. These include 12 liters of HTK chilled, 2 liters of normal saline chilled and 4 liters of frozen normal saline. (Alternatively centres using University of Wisconsin solution (UW) need to carry half the volume i.e 6 liters of UW) The ice box should contain flaked ice to the brim and pressure infusion bags. The perfusionist also helps set up lines with the aortic line pressure infusion bag at 100 mm Hg and the portal line without pressure, changes the fluids as they finish and assist the scrub nurse on the back table with the back table perfusion and in packing the organs.

The coordinator liaises with the donor and recipient teams and is the communication conduit with other teams, organizes the theatre for the donor team, is responsible for overseeing documentation of the case, winding up after the donor team leaves with the organ(s) and provides support to the donor family.

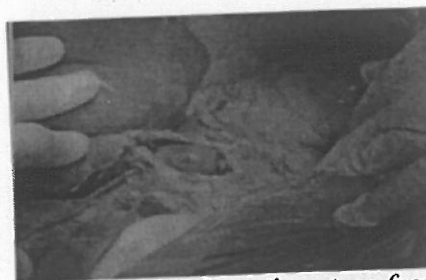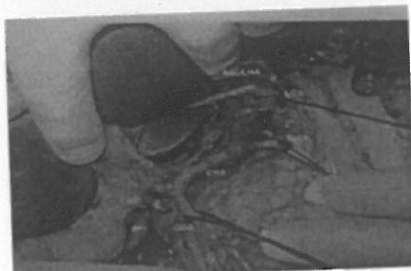## THE DONOR OPERATION

1. Discuss plans for the operation with the anaesthetist and renal teams regarding
  - i. Incision and sternotomy
  - ii. Heparinization
  - iii. Aortic clamping
  - iv. IVC clamping
  - v. Bleed out
2. The order of organ retrieval is as follows.
  - i. Heart/lung
  - ii. Liver
  - iii. Pancreas/intestine

- iv. Kidneys
- v. Corneas
- 3. Request the anaesthetist
  - a. To take a blood sample: 2 X 20 ml= 40ml for all tests. (Ensure 2 ml reaches blood bank for irregular antibody test).
  - b. Administer intravenous antibiotic
    - i. Cefazidime 2 g + Augmentin 1.2 g
    - ii. Ciprofloxacin 400 mg + Metronidazole 500 mg
  - c. Muscle relaxant
  - d. Prepare for heparinization : 300 units/kg approx 20,000 units (4 vials) for < 60 kg and 25,000 units (5vials) > 60kg
- 4. Position Patient :Supine with arms by the side
- 5. Check identity and consent
- 6. Clean and drape
- 7. Incision : Long midline laparotomy
  - a. Retract with Balfour retractor
  - b. Complete exploratory laparotomy
  - c. Divide falciform ligament and check that the liver is suitable
  - d. Check for accessory hepatic arteries
    - i. Right hepatic artery from superior mesenteric artery behind the bile duct
    - ii. Left hepatic artery from left gastric in the hepatogastric ligament

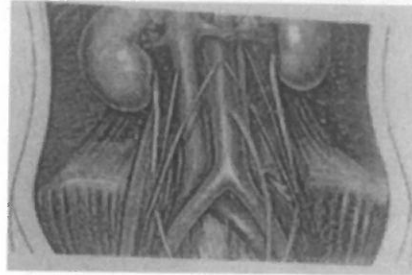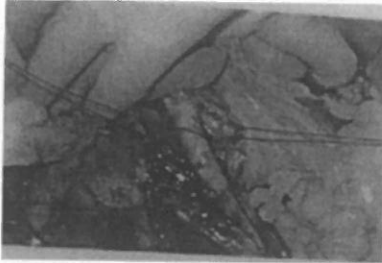


**Fig 1. Long midline laparotomy and sternotomy**

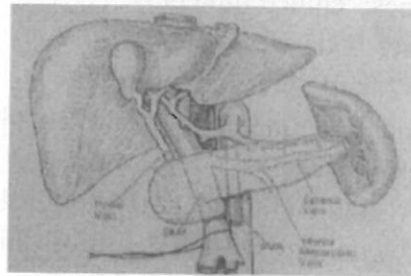
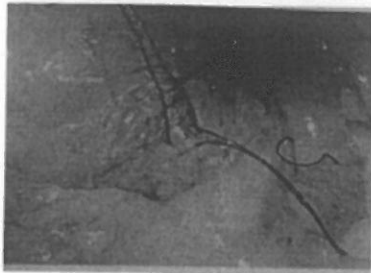


**Fig 2. Dissection of porta hepatis**      **Accessory left hepatic artery from left gastric artery**

8. Prepare for rapid cannulation/perfusion
  - a. Complete Cattell's maneuver mobilizing the colon on both sides to expose the retroperitoneum
  - b. Identify Ureters at pelvic brim
  - c. Pass ties around the origin of common iliac arteries/aorta
  - d. Prepare iliac veins and inferior vena cava for venting



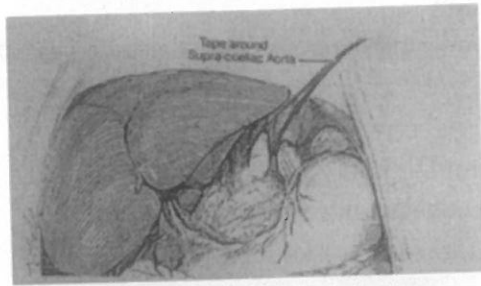
**Fig 3. Arterial access**



**Fig 4. Portal Venous access**

9. Warm phase dissection
  - a. Divide peritoneal attachments to the base of the liver
  - b. Expose retroperitoneum up to right/left renal vein and superior mesenteric artery
  - c. Mobilise duodenum to expose infra-hepatic inferior vena cava
  - d. Expose renal capsules on both sides and check kidneys for cysts/tumours
  - e. Pass two silk ties around the superior mesenteric vein at the root of the transverse mesocolon or around the inferior mesenteric vein
  - f. Ligate the inferior mesenteric vein
  - g. Pass a finger through the foramen of Winslow and open the lesser omentum
  - h. Divide the common bile duct just above the duodenum and ligate the duodenal side
  - i. Open the gall bladder and wash and suck out bile with saline using a 50 ml bladder syringe
  - j. Identify and loop the common hepatic artery between the gastroduodenal and splenic artery
  - k. May have to do a sternotomy by now to get access to porta/ supraceliac aorta (ensure pleura not opened and lungs collapsed when using Gigli saw. Achieve haemostasis with bone wax).
  - l. Incise right crus of diaphragm and loop umbilical tape around the supra celiac aorta.





**Fig 5. Looping supra celiac aorta**

10. Heparinize patient: 300 units/kg/body weight

11. Cannulation, perfusion and bleed out

a. Check sizes of cannulae

b. Perfusion

c. Perfusion volumes: 'chilled fluid only'

1. Aorta : 6 litres HTK at 100 mg Hg

2. Portal vein: 2 liters HTK (not pressurized)

3. Hang up fluids and run into lines and cannulae

4. Take cannulae to table

If using UW solution the suggested minimal volumes are as follows

a) In situ Aortic Flush: Adult 2-4 litres/Children 50 ml/kg

b) Ex vivo: Liver via Portal vein/bile duct : 1200 ml

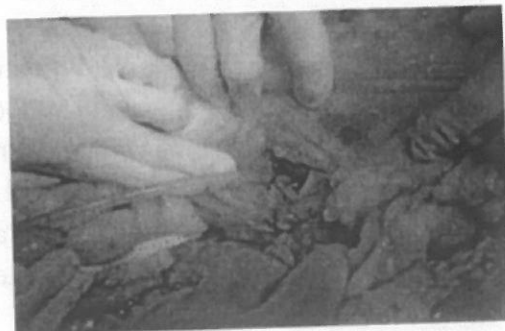
: Pancreas or Kidney : 300-500 ml

- *\*Caution: If using UW, the donor organ should be flushed free of UW solution before reperfusion to prevent potentially severe cardiovascular complications due to the high concentration of potassium in the solution.*

d. Ligate left common iliac artery

e. Cannulate right common iliac artery

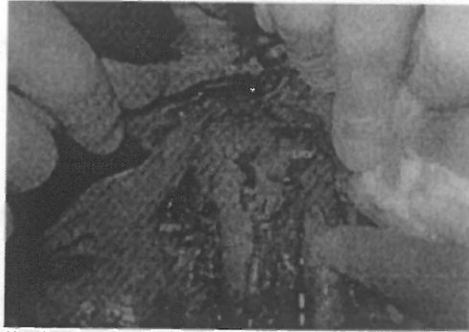
f. Cannulate superior/inferior mesenteric vein: place catheter tip at level of the pancreas



**Fig 6. Cannulation of superior mesenteric vein**

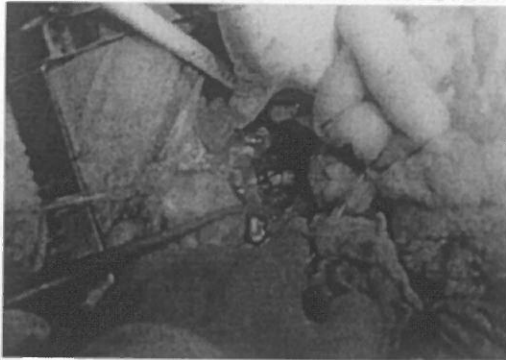
g. Place small swab between liver and diaphragm

- h. Clamp and tie supra coeliac aorta
- i. Immediately open suprahepatic inferior vena cava or infra hepatic inferior vena cava and bleed out with large bore suction cannula. Start perfusion simultaneously.

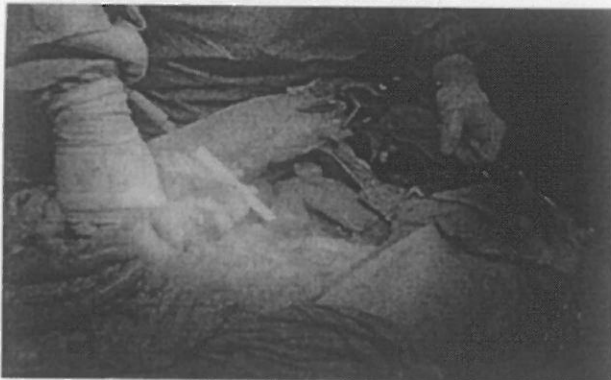

***Fig 7. Infrahepatic inferior vena cava for bleed out***

- j. Stop ventilation and patient monitoring and support
- k. Add topical ice and slush to liver and kidneys
- l. Recheck perfusion fluids flowing well and bleed out is clearing
- m. Trickle last 2 liters of aortic fluid



***Fig 8. Arterial cannulation***

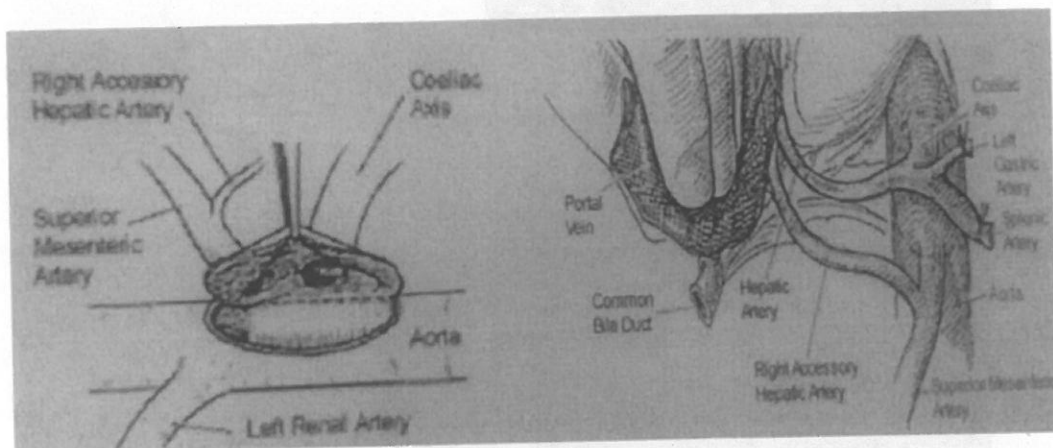


***Fig 9. Ice slush and perfusion simultaneously***

12. While the perfusion is going on, collect spleen and lymph nodes for tissue matching/HLA studies

13. Cold dissection

- a. Mobilise duodenum downwards, dividing gastroduodenal artery and expose portal vein
- b. Divide neck of pancreas anterior to portal vein/superior mesenteric vein
- c. Removal portal cannula and divide confluence of superior mesenteric vein/splenic vein
- d. Identify splenic artery and dissect to tail of pancreas and divide
- e. Divide left gastric artery distal to any accessory left hepatic artery
- f. Dissect left side of coeliac artery to expose aorta
- g. Dissect anterior aspect of aorta and divide slightly on the left side to visualize coeliac and superior mesenteric artery openings from inside
- h. If accessory right hepatic artery, include the superior mesenteric artery with the coeliac on one patch or divide between coeliac and superior mesenteric artery ensuring renal veins have aortic patches on both sides.
- i. Then divide superior mesenteric artery distal to right hepatic artery and carefully dissect right hepatic artery off head of pancreas
- j. Divide right crus of diaphragm and retroperitoneal tissue to the left of the inferior vena cava
- k. Divide infrahepatic inferior vena cava above renal veins by opening in midline and visualizing renal vein onsite clearly
- l. Place finger in suprahepatic inferior vena cava and divide diaphragm widely around the inferior vena cava/hepatic veins
- m. Mobilise right lobe of the liver exposing right adrenal and cutting through it (requires gentle traction by the assistant to avoid tearing the liver capsule)
- n. Divide remaining attachments and remove liver and inferior vena cava with attached tissues.



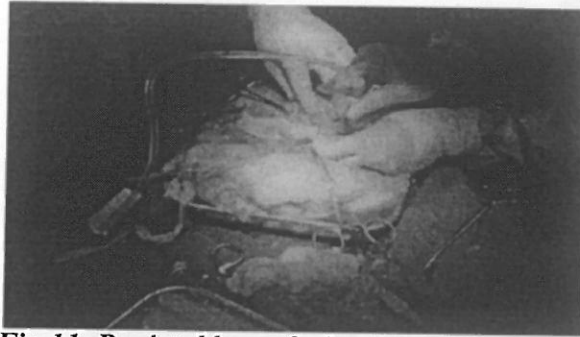
**Fig 10. Arterial patch harvest**



14. Back table perfusion


a. Flush portal vein, hepatic artery and common bile duct as follows.

- i. Portal vein : 1 litre HTK
- ii. Artery : 500 ml HTK
- iii. Bile duct : 500 ml HTK  
(1200 ml of UW solution as an alternative)



**Fig 11. Back table perfusion**

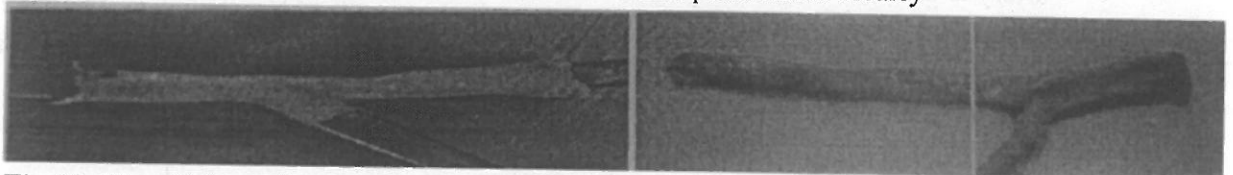
- b. Pack liver in fresh HTK solution/UW solution in a plastic bowl into two bags sucking out air
- c. Place in ice box and ensure adequate ice is present.



**Fig 12. Liver packed in a bowl and placed in ice**

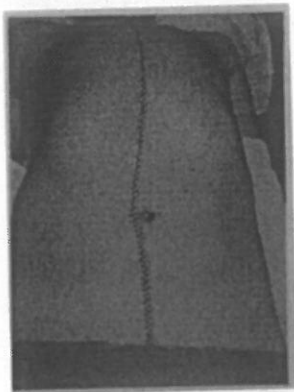
15. Kidney and vessel removal as normal with aortic patches and inferior vena cava patches by splitting both vessels in midline. Divide ureters below pelvic brim. Do not make window between gonadal vein and ureter.

- a. Perfuse renal artery with 200 ml HTK and pack in double bags in ice box
- b. Collect iliac veins and arteries. Store in HTK in small pots. Label clearly



**Fig 13. Iliac Vein and artery grafts harvested**

16. Close abdomen after swab count and instrument check.



**Fig 14. Completed Donor Operation**

17. In operation notes mention date and time of circulatory arrest clearly.

*Rapid perfusion*

In the donor becomes unstable or has a cardiac arrest, the following essential steps should be taken.

- a. Heparinise
- b. Place aortic and portal cannulae
- c. Open gall bladder and wash out bile
- d. Clamp the ascending aorta and bleed out through upper or lower inferior vena cava
- e. All further dissection to be done after cooling

**Other organ harvest during liver retrieval:**

Very often organs like the heart, pancreas and small bowel are also harvested along with the liver and certain precautions have to be kept in mind during such procedures.

**Special precautions:**

- a) Cardiac Retrieval : The cardiac team is hoping to retrieve as long an IVC segment as possible and this could seriously impinge on the hepatic veins. It is considered prudent to place a pack above the liver down to prevent hepatic vein damage. The warm ischaemia time also marginally increase till the heart is retrieval so adequate ice slush around the liver would be required.
- b) Pancreas: The pancreas team is looking out for adequate portal vein and splenic artery stumps and the liver team should exercise reasonable caution when dividing these vessels. The splenic artery is divided with a small stump protecting the common hepatic artery and the portal vein is divided just above the upper pancreatic margin. Utmost care is to be taken when the right hepatic artery arises from the margin. Utmost care is to be taken when the right hepatic artery arises from the SMA, which is divided only after the off take of the artery.
- c) Similarly during small bowel retrieval, the SMA and SMV are carefully dissected to ensure no vessels draining into the liver are damaged.

### **Post Procurement Care of the Donor:**

This vital step is the most important facet of organ retrieval – the esteemed donors body should be restored to an acceptable state without blemishes and defeats. Close the donor with great respect for the body, the donor family and so, by definition, respect for yourself. Remove all excess fluid and pack the body cavity with gauze/cotton wool to restore shape and close the skin with care and apply neat dressings to the incision site.

*Remember to complete all the forms!*

### **Important Attention Points:**

- a) Organ donation procedure is more than just go and get organs. It is an essential part of the organ transplantation and contributes for at least 50% to its success or failure.
- b) Clearly communicate your needs and requirements and your plane to the alien theatre- remember you are the alien and it is their theatre.
- c) There is a quite high possibility of encountering the donor family at the donor's bedside in the ICU/OT. Consequently, it is not the best place for the procurement surgeon at the beginning of the procedure.
- d) All information resulting from the surgery performed during organ procurement could be very important and useful for police and forensic departments and should be duly recorded.
- e) Warm the donor body during the whole organ procurement procedure to avoid coagulation problems.
- f) With older donors with a higher chance of malignancy, it could be useful to perform a laparotomy first, followed by general abdominal organ inspection and sternotomy.
- g) To avoid liver, heart, lungs and major vessel injury during sternotomy ask the anesthesiologist to lower the operating table and to stop ventilation for a while.
- h) The liver may appear swollen due to high CVP. In such case administer 20% albumin and furosemide and observe for changes.
- i) Remember there is no normal arterial anatomy of the liver – abnormal is the norm!
- j) After bleed out the abdominal organs become soft and easily tear- exercise extra caution during this phase.

### **Bench Procedure:**

During the back table procedure, the harvested graft is prepared for transplantation. The liver is kept immersed in the preservation fluid and surrounded by ice slush in a separate large bowl. All diaphragmatic and extra fatty tissue is removed and the vessels are carefully bared, The IVC is cleaned and checked for small opening from lumbar or phrenic veins which are suture ligated with fine prolene.

The CBD is never dissected completely taking care to keep the artery in contact with it at all times. The artery and the portal vein are cleared off pancreatic and fatty tissue and cleaned upto the adventitia taking care not to handle or pull on the intima.

